

Primary Non Hodgkin's Lymphoma of Cranial Dura Mater

Geetha NARAYANAN, Lakshmi HARIDAS, Jaisankar PUTHUSSERI

Regional Cancer Centre, Department of Medical Oncology, Kerala, INDIA

To the Editor,

Non-Hodgkin's lymphomas (NHL) rarely presents as a localized mass involving the dura. We present the case of a 55 year old lady with primary NHL of the dura.

A 55 year old lady presented with seizures of 3 month duration. There was no neurologic deficit. Computed tomogram (CT) of brain showed a lobulated dural based well enhancing lesion in left frontoparietal and right frontal region extending into the anterior interhemisphere fissure (Figure1). The lesion showed peripheral calcification. Underlying bone was eroded and there was midline shift to right. Magnetic resonance imaging (MRI) showed a sheet like extraaxial lesion of variable thickness involving the convexity subarachnoid space, enveloping the majority of left cerebral hemisphere. It extended into the subarachnoid space of interhemispheric fissure. It appeared hypointense on T1W1, isointense on T2W1 and hyperintense on flair sequence (Figure 2).

Patient underwent left frontoparietal craniotomy and tumor decompression. She presented to us following the surgery. On examination, she had palpable bilateral cervical lymphnodes. Her Hematology was normal, and lactate dehydrogenase was 521 IU. Histopathologic examination of the resected specimen showed infiltration by lymphoid nodules composed of small cleaved cells intermixed with large cells. Tumor cells were positive for Leucocyte common antigen (LCA), CD20 and negative for CD138. It was diagnosed as malignant lymphoma diffuse large B cell type. Bone marrow and other staging work up were normal.

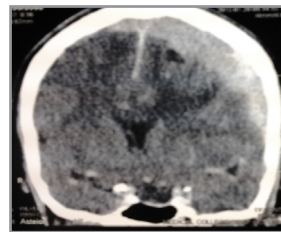


Figure 1. Coronal post contrast CT scan showing lobulated dural based well enhancing lesion in left frontoparietal region.

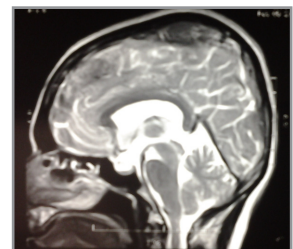


Figure 2. MRI showing the extraaxial lesion involving the convexity.

She received chemotherapy with rituximab, cyclophosphamide, vincristine, doxorubicin and prednisolone (RCHOP) for 6 courses. Local irradiation was planned, however, she refused the same. She remains in complete remission at 45 months.

Primary dural lymphoma is a rare disease with more indolent clinical behavior compared to primary central nervous system lymphoma. It represents less than 1% of all brain lymphomas. The majority of the reported cases are indolent marginal zone lymphomas, only very few cases of diffuse large B-cell lymphoma of the cranial dura has been reported.^{1,2} The symptoms depends on the location of the tumor and includes headaches, seizures, focal sensory or motor deficits, visual disturbances, nausea, vomiting, and ataxia. Single or multiple dural-based extraaxial lesions that diffusely enhance after gadolinium injection are the typical radiologic feature on MRI.³

They are usually mistaken as meningiomas. Since lymphoid tissue is absent in the dura, the pathogenesis of primary dural NHL is still unclear, many hypotheses have been formulated.³ Treatment consists of chemotherapy followed by local irradiation like other extranodal NHL. Role of intrathecal chemotherapy is unclear. Our patient is alive and in complete remission at 45 months after diagnosis.

REFERENCES

1. Iwamoto FM, Abrey LE. Primary dural lymphomas: a review. *Neurosurg Focus* 21: pE5, 2006
2. Said R, Rizk S, Dai Q. Clinical challenges of primary diffuse large B-cell lymphoma of the dura: case report and literature review. *ISRN Hematol* 2011: 945212. doi:10.5402/2011/945212.
3. Iwamoto FM, DeAngelis LM, Abrey LE. Primary dural lymphomas: a clinicopathologic study of treatment and outcome in eight patients. *Neurology* 66: 1763-1765, 2006.

Correspondence

Geetha Narayanan MD, DM
Professor and Head
Department of Medical Oncology
Regional cancer centre, Trivandrum 695011
Kerala, INDIA

Tel: 91-471-2522230
Fax: 91-471-2443498
e- mail: geenarayanan@yahoo.com