

Scrotal Ultrasonography Revisited for Non-Palpable Testicular Tumors in the Prepubertal Age: Case Report

Vural KESİK¹, Ayhan ABACI², Ediz YEŞİLKAYA², Bülent KURT³,
Sebahattin VURUCU⁴, Turan TUNÇ⁴

¹ Gülhane Military Medical Academy, Department of Pediatric Oncology

² Gülhane Military Medical Academy, Department of Pediatric Endocrinology

³ Gülhane Military Medical Academy, Department of Pathology

⁴ Gülhane Military Medical Academy, Department of Pediatrics, ANKARA

ABSTRACT

A 4-year-6 month old boy was seen for sexual precocity manifested by growth spurt, frequent penile erection, penile enlargement and pubic hair development. Scrotal ultrasonography -performed even though the testes were prepubertal, symmetric and bilaterally palpable- disclosed a tumor in the left testis. Left orchiectomy was performed and Leydig cell tumor was detected. Herein, we emphasize the role of scrotal ultrasonography in cases with gonadotropin-independent sexual precocity whereby the presence of non-palpable tumors should be excluded despite symmetrical testicles in the physical examination.

Key Words: Precocious puberty, Leydig cell tumor, Ultrasonography

ÖZET

Prepubertal Dönemde Palpe Edilemeyen Testiküler Tümörlerin Tanısında Skrotal Ultrasonografinin Yeri

Dört yaş 6 aylık erkek hasta büyümede hızlanma, sık penil ereksiyon, peniste büyüme ve pubik kıllanma şikayetleri ile başvurdu. Testis büyüklükleri prepubertal, simetrik ve bilateral palpe edilebilir olmasına karşın yapılan skrotal ultrasonografide sol testiste kitle tespit edildi. Sol orşiektomi yapıldı ve Leydig hücreli tümör olduğu tespit edildi. Bu makalede, testislerde ele gelen bir kitlenin olmadığı ve testislerin bilateral simetrik olarak palpe edildiği yalnızca erken puberteli olgularda, skrotal ultrasonografinin tanıda ne kadar önemli olduğu vurgulanmıştır.

Anahtar Kelimeler: Erken puberte, Leydig hücreli tümör, Ultrasonografi

INTRODUCTION

Precocious puberty is defined as the development of secondary sexual characteristics before the age of 8 in girls and 9 in boys. It is usually caused by premature activation of the hypothalamic-pituitary axis. If secondary sex characteristics develop without the activation of hypothalamic-pituitary axis, it is called gonadotropin-independent sexual precocity (GnRH-independent PP). GnRH-independent PP in males represents a group of heterogeneous disorders.¹

Prepubertal Leydig-cell tumors are hormonally active and associated with a painless testicular mass secreting testosterone that may lead to GnRH-independent PP. Marked asymmetry of enlarged testes or a unilateral enlargement suggest a Leydig cell tumor.^{1,2} They frequently occur around the age of 4-5 and are the most common non-germ cell tumors in both children and adults.² Patients with Leydig cell tumor usually presents with unilateral testis enlargement or a testicular mass. Scrotal ultrasonography (US) provides valuable information in these patients. In this report, we present a case with pseudo-precocious puberty due to a Leydig cell tumor and highlight the role of scrotal US in the diagnostic algorithm of impalpable testicular tumors.

CASE REPORT

A 4-year-6 month old boy presented to our endocrinology department with increased pubic hair, frequent penile erections, and enlargement of the penis which have started 6 months ago and progressively increased. In this period, rapid growth and weight gain with an accelerated growth velocity was noted (10 cm increase of height in 6 month).

In his medical history, he was born after an uneventful pregnancy. Delivery was normal. At birth, he weighed 3150 g; his length was 49 cm and head circumference was 36 cm. Developmental milestones were reported to be normal. The mother's height was 164 cm and the father's height was 175 cm, and the target height was estimated as 176 cm (target height SDS= -0.12). None of the family members had a history of sexual precocity, congenital adrenal hyperplasia and other endocrine diseases. In his past medical history there was no headache, vomiting, visual disturbances, polyuria,

polydipsia or any drug which could cause pubertal changes.

On physical examination, height was 106 cm (50-75 p), weight was 18 kg (50-75 p), and height age was 5 years. Bone age was determined as 6 years according to Greulich and Pyle atlas. Blood pressure was measured as 90/60 mmHg. Pubic hair was determined to be consistent with Tanner stage II. The penis was measured 8 x 2.1 cm with a normal urethral meatus on the glans (Figure 1A). The scrotum was mildly hyperpigmented. Testicular volume was measured bilaterally as 2 ml with the Prader orchidometer. Testicular volumes were symmetrical and no mass could be palpated. Transillumination showed no difference between the two testes. Patient was observed to have frequent penile erections during the physical examination. Acne and muscle hypertrophy were not present. The remaining systemic examination showed no pathological finding.

Laboratory examination showed that serum electrolytes, glucose, liver, renal function and thyroid function tests were within normal limits. Hormonal tests were as follows; 17-hydroxyprogesterone: 2.97 ng/mL (0.1-0.9), cortisol: 13.4 µg/dL (5-25), ACTH: 22.9 pg/mL (0-60), testosterone was 306.1 ng/dL (3-10), dehydroepiandrosterone sulfate was 82 ng/mL (100-835), FSH was 1.39 mIU/mL (0.2-3), LH was 0.58 mIU/mL (0.2-5). The possibility

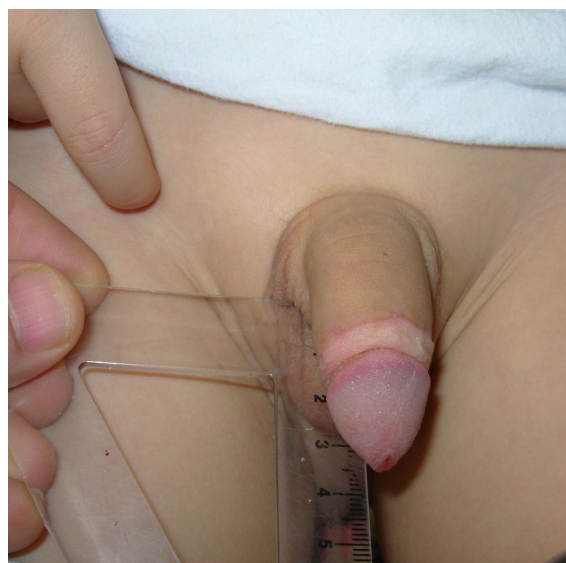

Figure 1A. Genitalia of the subject (hair, frequent penile erections, with enlargement of the penis.)

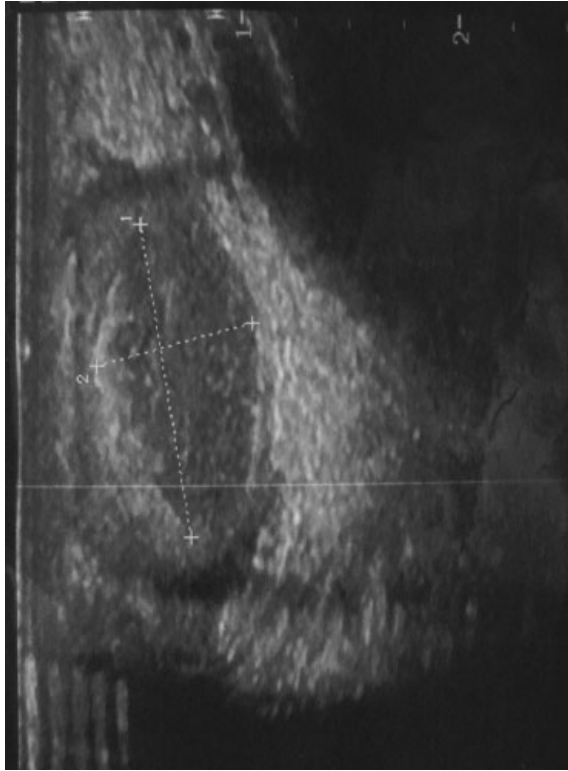


Figure 1B. Ultrasound image before surgery. Well-defined, oval, slightly heterogeneous, hypoechoic tumor with a partial surrounding hyperechoic halo is observed in the left testis.

that the precocity was due to central precocious puberty was excluded by the prepubertal response to GnRH and congenital adrenal hyperplasia was excluded by normal response to i.v. Synacten stimulation test. Basal levels of human chorionogonadotropin, carcinoembryonic antigen, alpha-fetoprotein, and CA-125 were within normal limits. McCune-Albright syndrome was excluded by the absence of cafe-au-lait lesions and a negative bone scan. Abdominal computerized tomography and abdominal US were evaluated as normal. Although the patient was considered to have GnRH-independent PP, all examinations failed to disclose any pathology; thus scrotal US was planned to exclude a testicular pathology even though both testes were symmetrical and no mass could be palpated. In scrotal US, an oval, slightly heterogeneous, hypoechoic tumor measuring 2 x 1 x 1 cm was easily recognized within the testis and it covered about 70% of the testis (Figure 1B). Doppler US showed hypervascularity in tumoral lesion (Figure 1C). The right testis was normal. The lesion was considered to be a testoste-

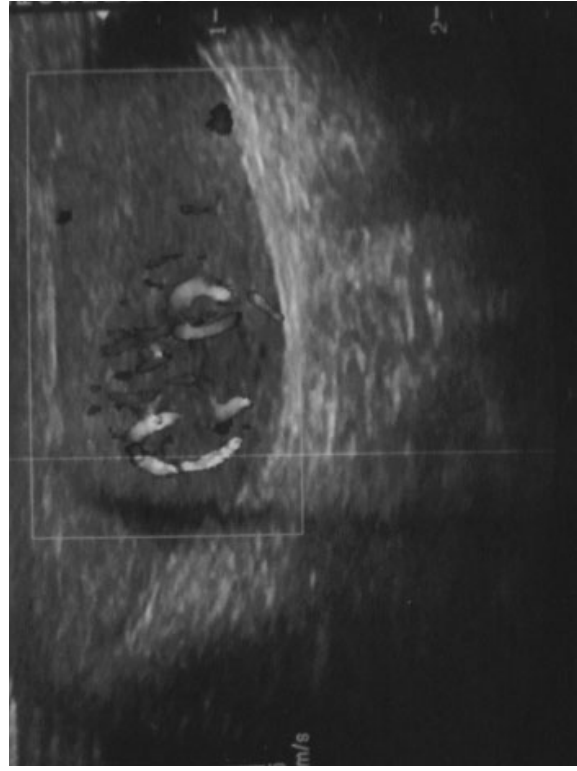


Figure 1C. Doppler US show hypervascularity in the tumoral lesion.

rone-secreting tumor; thus left orchiectomy was performed. After surgery, histological examination of the specimen showed a tumor composed of large and round or polygonal cells with abundant granular eosinophilic cytoplasm and round central nucleus (Figure 1D). There were no mitotic figures, necrosis or atypia. The tumor cells showed widespread positivity for vimentin, inhibin and Melan-A (Figure 1E). It was diagnosed as Leydig cell tumor.

Symptoms and signs of the patient rapidly improved after the operation and serum hormone levels returned to normal (testosterone was 10 ng/dL (3-10)). The patient had normal hormonal levels followed by regression of penile erection and pubic hair development within the 6 months after surgery.

DISCUSSION

Testicular evaluation is paramount during the study of puberty in boys. The size and symmetry provide clues for categorization of the potential cause of precocious puberty. Prepubertal-sized testes consis-

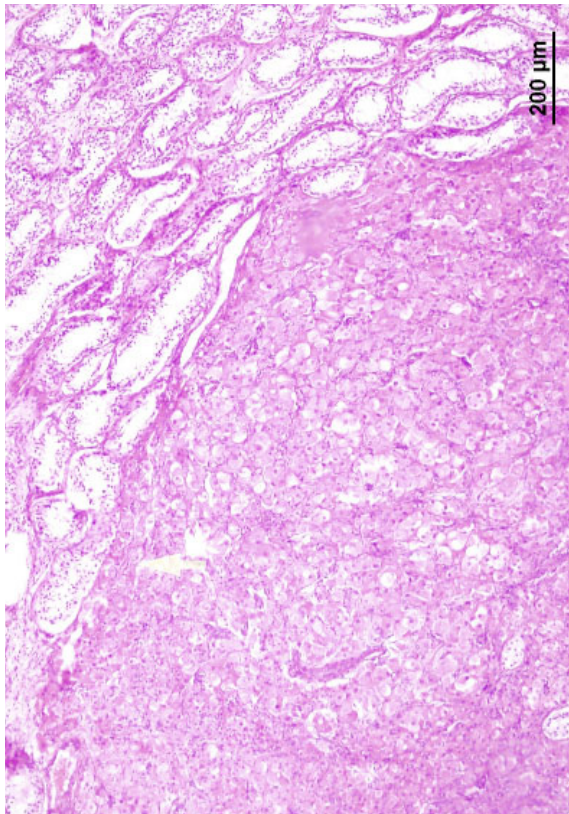


Figure 1D. Large and round or polygonal cells with abundant granular eosinophilic cytoplasm (HE x100).

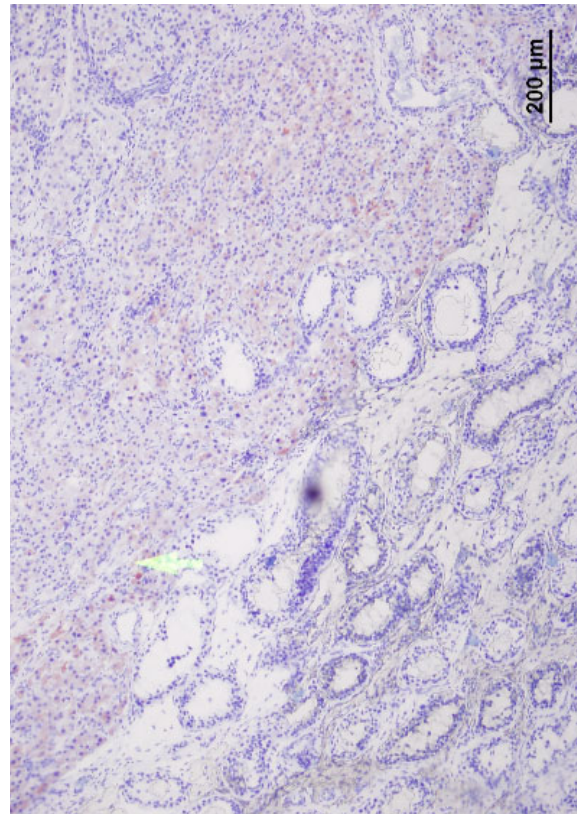


Figure 1E. Inhibin positivity in tumor cells (Immunohistochemistry, inhibin x100).

tent with staging of puberty suggest a cause other than pubertal hypothalamic-pituitary-gonadotropin function. Marked asymmetry of enlarged testes or unilateral enlargement suggests a Leydig cell tumor, hyperplastic adrenal rest tissue, as occurs in inadequately treated CAH males or previous damage to the smaller testis, such as after surgery, with hypertrophy of the larger testis.^{1,3} However, testicular tumor may be present even though testes are small and symmetrical on physical examination.³ Likewise, our patient had symmetric prepubertal testicles with no palpable mass.

Testicular tumors are very rare and always benign in pediatric age, accounting only for 1-2% of all pediatric tumors.² Among those, 1-3% are the Leydig cell tumors (4.5). It usually presents with a testicular mass (95%), accompanied or preceded by hormonal changes in 20% of the cases, with feminization in the adult and masculinization in the child and represented by a deepening voice, pubic hair, acne, gynecomastia, somatic growth, or penile

growth associated with a painless testicular mass.^{4,6} Our patient had increased pubic hair, frequent penile erections with enlargement of the penis, and accelerated growth velocity within last 6 months.

Several publications have described the value of scrotal US in detection of testicular tumors.³ Recent advances in US technology allow identification of lesions as small as 1 mm, but cannot provide specific diagnostic information.⁶ In another study, US was shown to be highly sensitive in the detection of intratesticular masses (96.6%) but its specificity was rather low (44.4%).⁷ Even though scrotal US is so valuable for detecting testicular masses, there are several cases of Leydig cell tumor in the literature which have been detected by magnetic resonance imaging after a negative scrotal US.⁸ Ilondo et al.³ have defined the diagnosis of a Leydig cell tumor in childhood as rather difficult and recommended testicular US for all precocious puberty patients that have testicular abnormality. This case report indicates the need and importance of scrotal

US in patients with GnRH-independent PP that have prepubertal and symmetrical testes without a palpable mass.

Clinical hormonal manifestations have been reported to improve in the literature after the excision of Leydig cell tumor.^{2,3,6} Both clinical manifestations and serum hormone levels rapidly improved in our case.

As for conclusion; we point out the possibility of an impalpable testicular tumor and therefore the need for scrotal US in patients with clinical and laboratory findings of GnRH-independent PP. This is also true even if they have prepubertal and symmetrical testes without a palpable mass.

REFERENCES

1. Lee PA, Houk CP. Puberty and its disorders. in: Pediatric Endocrinology. Lifshitz F (ed). Fifth ed. New York, Healthcare, 2007: 273-304.
2. Petkovic V, Salemi S, Vassella E, et al. Leydig-cell tumor in children: variable clinical presentation, diagnostic features, follow-up and genetic analysis of four cases. *Horm Res* 67: 89-95, 2007.
3. Hondo MM, van den Mooter F, Marchal G, et al. A boy with Leydig cell tumor and precocious puberty: Ultrasonography as a diagnostic aid. *Eur J Pediatr* 137: 221-227, 1981.

4. Corrie D, Norbeck JC, Thompson IM, et al. Ultrasound detection of bilateral Leydig cell tumors in palpable normal testes. *J Urol* 137: 747-8, 1987.
5. Papatsoris AG, Triantafyllidis A, Gekas A, et al. Leydig cell tumor of the testis. New cases and review of the current literature. *Tumori* 90: 422-423, 2004.
6. Sheynkin YR, Sukkarieh T, Lipke M, et al. Management of nonpalpable testicular tumors. *Urology* 63: 1163-1167, 2004.
7. Coret A, Leibovitch I, Heyman Z, et al. Ultrasonographic evaluation and clinical correlation of intratesticular lesions: A series of 39 cases. *Urology* 76: 216-219, 1995.
8. Kaufman E, Akiya F, Foucar E, et al. Viralization due to Leydig cell tumor diagnosis by magnetic resonance imaging. Case management report. *Clin Pediatr* 29: 414-417, 1990.

Correspondence

Dr. Vural KESİK
Gülhane Askeri Tıp Akademisi
Pediyatrik Onkoloji Bilim Dalı
06018 ANKARA

Tel: (0.312) 304 43 65

Fax: (0.312) 304 43 81

E-mail: vural73@yahoo.com