

# FDG-PET/CT Imaging-Based Target Volume Delineation for Preoperative Conformal Radiotherapy of Rectal Carcinoma

Melek N. YAVUZ<sup>1</sup>, Erkan TOPKAN<sup>1</sup>, A. Aydın YAVUZ<sup>1</sup>, Mehmet AYDIN<sup>2</sup>, Cem ONAL<sup>1</sup>, Mehmet REYHAN<sup>2</sup>, Ayse KOTEK<sup>1</sup>, Berrin PEHLIVAN<sup>1</sup>, A. Fuat YAPAR<sup>2</sup>

<sup>1</sup> Baskent University Faculty of Medicine, Department of Radiation Oncology, Adana Medical and Research Center

<sup>2</sup> Baskent University Faculty of Medicine, Department of Nuclear Medicine, Adana Medical and Research Center, Adana, TURKEY

## ABSTRACT

Positron emission tomography (PET) has the potential to improve staging and radiation treatment-planning (RTP) for tumors in various sites. We compared computed tomography (CT) with co-registered 18F-fluorodeoxyglucose (FDG)-PET-CT as the basis for delineating gross tumor volume (GTV) in patients with rectal carcinoma undergoing preoperative three-dimensional conformal radiotherapy (3D-CRT).

Twenty-three patients diagnosed with localized rectal carcinoma who were candidates for preoperative chemoradiation were evaluated using both CT and PET imaging. For each patient, two 3D-CRT plans were created using the CT and PET-CT fusion data sets. GTV was contoured on both CT (GTV<sub>CT</sub>) and co-registered PET-CT (GTV<sub>PET-CT</sub>) images. The resulting GTV<sub>CT</sub> and GTV<sub>PET-CT</sub> images were analyzed comparatively.

The median GTV<sub>PET-CT</sub> (40 cm<sup>3</sup>) was significantly greater than the median GTV<sub>CT</sub> (25.7 cm<sup>3</sup>) (p= 0.0001). The median difference between GTV<sub>PET-CT</sub> and GTV<sub>CT</sub> was 65%. The intersected tumor volume determined by the two methods was median 19.7 cm<sup>3</sup>, and tumor volumes remaining outside CT was median 15.2 cm<sup>3</sup>. The median volume identified by PET but not by CT (PEToutCT) was 35% of GTV<sub>PET-CT</sub>, indicating the possibility of a geographic miss in GTV.

Co-registration of PET and CT information in localized rectal cancer may improve the delineation of GTV and theoretically reduce the likelihood of geographic misses, thus potentially having a positive impact on treatment planning.

**Keywords:** Rectal cancer, Positron emission tomography, Radiation therapy, Gross target volume, Treatment planning

## ÖZET

### Rektum Kanserinin Preoperatif Radyoterapisinde BT İle PET-BT Bazlı 3-Boyutlu Konformal Radyoterapi Planlamalarının Karşılaştırılması

Pozitron emisyon tomografisi (PET) birçok tümörün evrenmesi ve radyoterapi planlamasında potansiyel bir kazanç sağlamıştır. Rektum kanserinin preoperatif konformal radyoterapisi öncesi bilgisayarlı tomografi (BT) ile 18F-fluorodeoksiglukoz pozitron emisyon tomografisi/bilgisayarlı tomografi (FDG-PET/BT) bazlı 3-boyutlu tedavi planlamaları karşılaştırılmıştır. Kliniğimizde rektum kanseri tanısı ile preoperatif kemoradyoterapi planlanan 23 hasta çalışmaya alınmıştır. Tüm hastaların tedavi öncesinde, tedavi pozisyonunda olacak şekilde PET ve BT görüntüleri elde edilmiştir.

Her hastanın gros tümör volümü (GTV) önce BT (GTVCT), sonra PET/BT (GTVPET-CT) görüntülerinde kontrol edilmiş; GTVCT ve GTVPET-CT değerleri ölçülmüştür.

Ortanca GTVPET-CT (40 cm<sup>3</sup>), GTVCT (25.7 cm<sup>3</sup>)'den daha büyük olarak belirlenmiş ve aradaki fark istatistiksel olarak anlamlı bulunmuştur (p = 0.0001). GTVPET-CT ve GTVCT arasındaki fark %65' dir. Her iki yöntemle kesişen ortanca tümör volümü 19.7 cm<sup>3</sup> ve BT dışı ortanca tümör volümü 15.2 cm<sup>3</sup> olarak ölçülmüştür. BT dışı ortanca tümör volümü GTVPET-CT'nin %35'i olup tümörün coğrafik hata ile kaçırılabilceğini göstermektedir.

Bu sonuçlar rektum kanserinin preoperatif konformal radyoterapi planlamasında PET/BT kullanımının hedef volümün daha doğru belirlenebilmesi ve coğrafik hatanın minimuma indirilmesinde önemli olduğunu düşündürmektedir.

**Anahtar Kelimeler:** Rektal kanser, Pozitron emission tomografi, Radyoterapi, gross target volum, Tedavi planlaması

## INTRODUCTION

High-dose preoperative chemoradiotherapy has significantly improved the rates of sphincter preservation, local control and survival in localized rectal carcinoma.<sup>1-4</sup> One way to improve on current results is to increase the radiation dose applied to the tumor tissue; however, further dose escalation is limited by toxicity to adjacent normal tissue. In this context, three-dimensional conformal radiation therapy (3D-CRT), intensity-modulated radiotherapy (IMRT) and helical tomotherapy have shown great promise.<sup>5-8</sup> The current standard imaging technique used in radiation therapy treatment planning (RTP) is conventional computed tomography (CT), a technique that has inherent disadvantages in determining primary tumor and lymphatic extension due to limited sensitivity and specificity.<sup>9</sup> Thus, the images generated by conventional CT tend to either under- or overestimate tumor boundaries, potentially leading to unnecessarily large radiation therapy (RT) portals or geographic misses.

Clearly, a more accurate definition of RT target volumes would reduce geographic misses in rectal carcinoma RTP. Tumor delineation and noninvasive tissue characterization is important for effective treatment selection, planning and monitoring in radiation oncology.<sup>9-12</sup> Although CT has a relatively higher spatial resolution than other imaging methods, its value in rectal cancer RTP is significantly diminished by its lower specificity. Functional 18F-fluorodeoxyglucose positron emission tomography (FDG-PET) has been shown to have higher sensitivity and specificity than anatomic CT in the detection of primary tumors, lymphatic extensions and distant metastases.<sup>13-17</sup> In recent years, the co-registration of CT images with FDG-PET images has attracted increasing attention for staging and RTP of several tumor sites, including the rectum. The fu-

sion of PET signals with CT has proved highly accurate for localizing pelvic disease.<sup>18</sup> The specific activity of the FDG-PET signal improves target-volume definition and may result in more uniform assessment of target volume by different radiation oncologists.<sup>19,20</sup> More recently, investigations of the reliability of PET-determined GTVs for macroscopic lesions that are amenable to appropriate surgery or RT have shown that PET information can change treatment decisions.<sup>21,22</sup> Applied to external-beam RT, PET technology may allow the establishment of a standardized and highly reproducible approach to defining tumor volume. PET-CT-based RTP has been shown to significantly alter RT fields in patients with various tumors, including cancers of the head and neck, lung, pancreas, esophagus and cervix.<sup>9,20,23-28</sup> Only a few published studies have addressed the potential benefit of FDG-PET for tumor staging, predicting the response to preoperative treatment, and defining the target volume in rectal cancer.<sup>20,22,29-35</sup>

The purpose of this current study was to compare the CT method with co-registered PET-CT as the basis for GTV delineation in patients with rectal carcinoma undergoing preoperative 3D-CRT.

## METHODS AND MATERIALS

Twenty-three patients with pathologically confirmed rectal adenocarcinoma and candidates for radiotherapy in a preoperative setting with concomitant chemotherapy were prospectively enrolled. Other eligibility criteria were as follows: Eastern Cooperative Oncology Group performance status (PS) of 0 to 2; age between 18 and 75 years; determination of disease extent by proctoscopy, colonoscopy and radiographic imaging; no prior chemotherapy or abdominal irradiation; no contraindication for PET-CT imaging. The clinical stage was defined accor-

ding to the 2002 American Joint Committee on Cancer – International Union Against Cancer (AJCC-UICC) classification.<sup>36</sup> All patients provided written informed consent, and the institutional ethics committee, in accordance with the Helsinki Declaration on human projects, approved the study design.

### CT and PET Imaging

Prior to CT and PET imaging, patients were immobilized in the supine position with arms crossed on the thorax with a “knee-fix” cushion under the knees. Before imaging, simulator lasers (Acuity, Varian Medical Systems, Palo Alto, CA, USA) were used to align and mark patients to define the coordinate system that would be used for treatment planning. For PET-based planning, eligible patients were evaluated using the combined PET-CT system (Discovery-STE 8, General Electric Medical System, Milwaukee, WI, USA). The patients were administered an intravenous dose of FDG (370-555 MBq, 10-15 mCi) after fasting for at least 6 hours. Preinjection blood glucose was measured to ensure that levels were below 150 mg/dl. During the distribution phase, patients lay supine in a quiet room. Patients were scanned on a flat-panel carbon-fiber composite table insert, with combined image acquisition beginning 60 minutes after FDG injection. An unenhanced CT scan (5 mm slice thickness) from the base of the skull to the inferior border of the pelvis was acquired first using a standardized protocol with 140 kV, 80 mA. The subsequent PET scan was acquired in 3D mode from the base of the skull to the inferior border of the pelvis (6-7 bed positions, 3 min/position) without repositioning the patient on the table. Both CT and PET images were acquired with the patient breathing shallowly. Attenuation was corrected using the CT images. Areas of FDG uptake were categorized as malignant based on location, intensity, shape and size, and visual correlated with CT images to differentiate physiologic from pathologic uptake. The processed images were displayed in coronal, transverse and sagittal planes. CT- and PET-CT based treatment planning for each patient was performed using an Eclipse 7.5 RTP system (Varian Medical Systems, Palo Alto, CA, USA), which includes all standard RTP features as well as a DICOM image reader and automated image registration software.

### Target Volume Delineation

The target volumes were defined by a radiation oncologist (MNY) with specific experience in rectal cancer treatment, according to the guidelines of International Commission on Radiation Units and Measurements Report 62.<sup>37</sup> For each patient, gross tumor volume were first delineated on CT images to obtain GTV<sub>CT</sub>, and then on PET/CT fused images to obtain GTV<sub>PET-CT</sub>. PET images were interpreted by setting window and level using a method previously shown by Erdi et al. and Bassi et al.<sup>30,38</sup> to achieve accurate target definitions. In this protocol, we first set the upper window level the value of the highest-intensity pixel in the lesion, and then set the lower window level to 40% of this maximum level.

### Statistical Analysis

On the basis of the available literature on rectal carcinoma tumor volume delineation, we hypothesized that integration of PET into RTP would change the target volumes in approximately 30% of the patients.<sup>20,29,30</sup> To detect such a change with a 95% confidence interval of 5%-55%, we needed to enroll at least 13 patients. The GTV<sub>PET-CT</sub> was compared with GTV<sub>CT</sub> using a Wilcoxon signed-rank test for paired data. Results were expressed as median (min-max). Differences were considered significant when the two-tailed p-value was less than 0.05. Also included in the statistical analysis was the volume identified by PET but not by CT (PEToutCT), and the volume common to CT and PET (CT&PET).

## RESULTS

The patient characteristics are summarized in Table 1. A comparison of the tumor volumes estimated by the two methods showed that the median GTV<sub>PET-CT</sub> (40 cm<sup>3</sup>) was significantly greater than the GTV<sub>CT</sub> (25.7 cm<sup>3</sup>) (p= 0.0001; Wilcoxon rank test). The median difference between GTV measured by the two methods was 65% (Table 2). Comparisons of additional volume parameters measured by PET/CT and CT alone are shown in Table 2 and Figure 1. The common volume measured by the two methods (intersected tumor volume) was 19.7 cm<sup>3</sup>, and tumor volumes remaining outside CT was

15.2 cm<sup>3</sup>. The median volume identified by PET but not by CT (PEToutCT) was 35% of GTV<sub>PET-CT</sub>, indicating the possibility of a geographic miss in GTV.

## DISCUSSION

We compared CT- and PET-CT-based target volume delineation techniques for localized rectal carcinoma, determining their respective effects on 3D-CRT planning. Our results revealed that PET-CT-based target volume delineation significantly increased the GTV compared to CT-based delineation, an outcome that could alter the RT portals in unresectable or medically inoperable patients where a boost in RT doses was potentially a great concern.

Preoperative chemoradiotherapy is the current standard treatment option for localized rectal cancer because it provides a chance for sphincter preservation and achieves better local control in a significant percentage of patients, translating into improved quality of life and overall survival rates compared to postoperative RT protocols.<sup>39</sup> In the absence of local control, cure of rectal carcinoma is not possible; therefore, optimal dose delivery is necessary to ensure successful local tumor control. This can best be achieved by avoiding geographic misses. Compared to postoperative RTP, one important advantage of preoperative RTP is its reliance on readily identifiable, intact tumor tissue, which helps to better define target volumes. Currently, CT-based definition of target and organ at-risk volumes remains the reference standard for curative 3D-CRT.<sup>40</sup> However, the accurate definition and contouring of the boundaries of the primary tumor and its locoregional extensions are difficult using conventional CT-based GTV delineation methods. Tumoral extensions into the rectal wall or perirectal tissue structures usually are not visible, and significant inter-observer variation has been demonstrated when CT data is utilized as the sole RTP tool. When used in conjunction with anatomic CT as a functional imaging method, FDG-PET may provide additional data that may lead to better definition of target volumes and aid in overcoming variability in interpretations between radiation oncologists.<sup>41</sup>

Additional data provided by PET has led to impressive changes in physicians' perception of tumor extension, and has prompted adaptation of this method

**Table 1.** Characteristics of study population

Characteristics	n
Patients	23
Age (years)	
Median	58
Range	18 - 75
Gender	
Male	14
Female	9
Performans	
Median	1
Range	0-2
Clinical Stage	
T3 N0 M0	8
T3 N1 M0	9
T3 N0 M1	2
T4 N0 M0	4

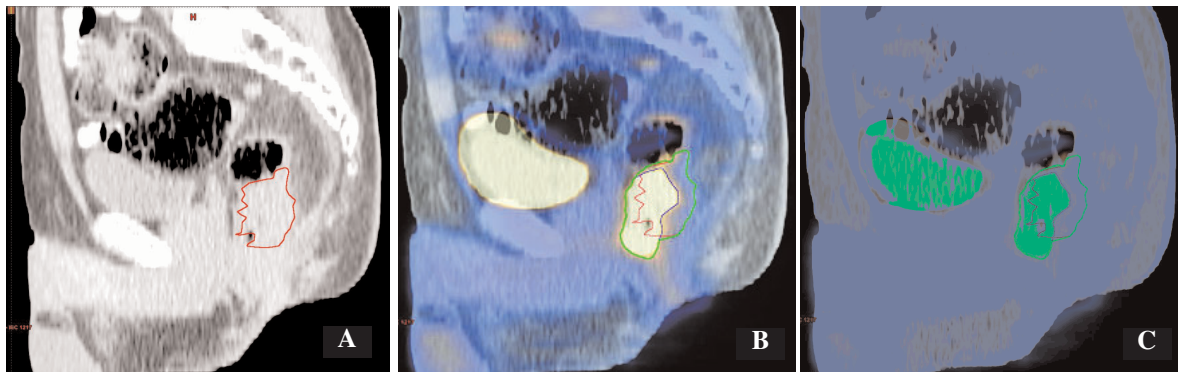
*Abbreviations:* AJCC: American Joint Committee on Cancer; T: tumor extension; N: lymph-nodal disease; M: distant metastasis.

for defining treatment volumes in a broad variety of cancers, including lung, esophagus, head-and-neck, anal canal, pancreas, malignant lymphoma, Hodgkin's disease and rectal carcinoma.<sup>9,19,20,24,26,30,42-58</sup> FDG-PET, with its higher sensitivity, specificity and accuracy, is suitable for detec-

**Table 2.** Volumes (cc) identified after fusion of PET and CT

Volumes	Median	Min-Max
CT - GTV	25.7	3.17-135.6
PET/CT - GTV	40	10.6-177.7
PEToutCT	15.2	3.9-133
CT&PET	19.7	0.7-123.4

*Abbreviations:* PET/CT-GTV: the composite volume between PET and CT; PEToutCT: the volume identified by PET but not by CT; CT&PET: the common volume of the two image modalities (CT and PET).



**Figure 1.** Representative image of patient with different GTV delineations; CT (A), PET (B) and coregistered PET-CT (C)

ting rectal-cancer tissue and determining its boundaries for the purpose of staging/restaging of disease in the pelvis or for staging of metastatic diseases.<sup>22</sup> The additional data provided by FDG-PET may influence RT portals. Furthermore, the intent of treatment may change from curative to palliative, potentially sparing a significant percentage of patients from unnecessary debilitating RT and hastening the initiation of full-dose chemotherapy protocols.<sup>30,32</sup>

Incorporation of composite PET-CT images has had a significant impact on GTV delineation in rectal carcinoma RTP in studies by Ciernik et al, Lammering et al and, more recently, by Bassi et al.<sup>20,29,30</sup> Compared to CT-based delineation, PET-CT based delineation was shown to produce an increase in GTV in 3 of 6 cases (50%) of preoperative rectal cancers in the study of Ciernik et al.<sup>20</sup>, an increase in GTV that led to a 20% increase in planning target volume (PTV). Lammering et al.<sup>29</sup> studied a group of 40 patients with rectal carcinoma in a preoperative setting and demonstrated that the inclusion of PET information significant increased GTV ( $GTV_{CT} = 95.9 \pm 57.1 \text{ cm}^3$  versus  $GTV_{PET} = 128.3 \pm 80.4 \text{ cm}^3$ ;  $p < 0.001$ ), a difference that corresponded to a 33.8% increase. Bassi et al.<sup>30</sup> compared the  $PET-CT_{GTV}$  and  $CT_{GTV}$  in a preoperative setting among 25 consecutive patients diagnosed with rectal carcinoma who were candidates for RT with/without concurrent chemotherapy, a cohort similar to our own. The use of PET information in conjunction with CT revealed a significant change in GTV, with a mean difference of  $19.6 \pm 29.0 \text{ cm}^3$  ( $p < 0.00013$ ), amounting to a 25.4% enlargement in GTV. The 65% enlargement of GTV with inclu-

sion of PET information demonstrated in the current study is consistent with these previous reports.

In the present cohort, CT- and PET-estimated volumes differed significantly. Neither CT nor PET is 100% sensitive for detecting tumor extension; thus, for clinical purposes, we used the co-registered PET-CT volumes, reasoning that the delineated composite volume would maximize target volume coverage. Supporting our choice, Ciernik et al.<sup>22</sup>, using an automated PET-based algorithm for RTP of preoperative rectal carcinoma, previously showed that the true anatomic-pathologic tumor extension might exceed the radiologic volume identified on CT images. Considering this fact, it is reasonable to assume that composite PET-CT information could be useful in preventing the risk of a geographic miss. An important drawback of such an approach is that it contradicts the logic of conformal RT, in which a high therapeutic index is achieved by delivering high radiation doses to a precisely defined volume while sparing neighboring healthy tissues. The availability of more specific radiotracers and/or additional studies designed to correlate FDG-PET and pathological findings will be needed to resolve this issue.

Although concurrent chemoradiotherapy is the standard treatment option for medically unfit rectal cancer patients, outcomes are highly variable, ranging from complete response to no response. Pathological complete remission was reported to range from 8% to 29%, depending on the stage at presentation, regimen of chemotherapy and dose of radiation administered.<sup>59-63</sup> In the remaining 71% to 92% of patients, intact viable tumor tissue remained, justifying escalated RT doses for better local

control. In this context, the additional information provided by PET could be helpful in accurately defining the boost volume for conformal RT techniques. Furthermore, the additional volume and intratumoral functional variations uniquely identified by PET may have an even more critical importance in the near future when so-called dose-painting IMRT becomes widely used in clinical practice, opening the possibility of controlled and reproducible internal-dose escalation to functionally interesting areas of the tumor. With the use of more specific functional PET tracers, this high-precision RT technique could help enormously in resolving the reciprocal problems of over- and underestimation of GTV and mitigate their negative consequences for the radiation management of tumors at many sites, including the rectum.

There are two major drawbacks of PET-based target volume delineation studies that are also relevant here. First, available reports of GTV delineation based on PET images have employed varied approaches, but have typically used standardized uptake value. To facilitate comparison with the available literature, we utilized a signal threshold of 40%, similar to that of Bassi et al.<sup>30</sup>, in our current cohort. Second, the absence of reliable data correlating PET- or co-registered PET-CT-based GTVs with true tumor volumes in pathologic specimens limits our ability to draw more precise conclusions. Although such correlational studies would be worthwhile, the logic of preoperative rectal cancer chemoradiation studies unfortunately has apparently precluded formally addressing this question. However, this issue deserves to be studied in patients planning to first undergo a curative resection. Such evidence, we believe, can safely be extrapolated to rectal cancer patients who are candidates for preoperative chemoradiation.

## CONCLUSIONS

The results of our current study demonstrate the usefulness of PET-CT-based target volume delineation in localized rectal cancer patients destined for preoperative chemoradiotherapy. In cases where an additional radiation boost dose to the primary tumor site is needed, the observed increase in GTV (median, 65%) could be relevant, reducing the risk of geographic misses associated with CT-based

RTP. This benefit could potentially translate into better rates of local control and survival. However, further clinical studies are needed to reach more precise conclusions.

## REFERENCES

1. Glynne-Jones R, Mathur P, Elton C, et al. The multidisciplinary management of gastrointestinal cancer. Multimodal treatment of rectal cancer. *Best Pract Res Clin Gastroenterol* 21: 1049-70, 2007.
2. Sauer R, Becker H, Hohenberger W, et al. German Rectal Cancer Study Group. Preoperative versus postoperative chemoradiotherapy for rectal cancer. *N Engl J Med* 351: 1731-1740, 2004.
3. Frykholm GJ, Glimelius B, Pahlman L. Preoperative or postoperative irradiation in adenocarcinoma of the rectum: final treatment results of a randomised trial and evaluation of late secondary effects. *Dis Colon Rectum* 36: 564-572, 1993.
4. Glimelius B, Isacson U, Jung B, et al. Radiotherapy in addition to radical surgery in rectal cancer: Evidence for a dose response effect favouring preoperative treatment. *Int J Radiat Oncol Biol Phys* 37: 281-287, 1997.
5. Engels B, De Ridder M, Tournel K, et al. Preoperative Helical Tomotherapy and Megavoltage Computed Tomography for Rectal Cancer: Impact on the Irradiated Volume of Small Bowel. *Int J Radiat Oncol Biol Phys* 74: 1476-1480, 2009.
6. Ippolito E, Mertens I, Haustermans K, et al. IGRT in rectal cancer. *Acta Oncol* 47:1317-24, 2008.
7. Ballonoff A, Kavanagh B, McCarter M, et al. Preoperative capecitabine and accelerated intensity-modulated radiotherapy in locally advanced rectal cancer: A Phase II trial. *Am J Clin Oncol* 31: 264-270, 2008.
8. Gunnlaugsson A, Kjellén E, Nilsson P, et al. Dose-volume relationships between enteritis and irradiated bowel volumes during 5-fluorouracil and oxaliplatin based chemoradiotherapy in locally advanced rectal cancer. *Acta Oncol* 46: 937-944, 2007.
9. van Baardwijk A, Baumert BG, Bosmans G, et al. The current status of FDG-PET in tumour volume definition in radiotherapy treatment planning. *Cancer Treat Rev* 32: 245-260, 2006.
10. Bruehlmeier M, Roelcke U, Schubiger PA, et al. Assessment of hypoxia and perfusion in human brain tumors using PET with <sup>18</sup>F-fluoromisonidazole and <sup>15</sup>O-H<sub>2</sub>O. *J Nucl Med* 45: 1851-1859, 2004.
11. Strauss LG, Conti PS. The applications of PET in clinical oncology. *J Nucl Med* 32: 623-648; 649-650, 1991.
12. Janssen MH, Aerts HJ, Ollers MC, et al. Tumor delineation based on time-activity curve differences assessed with dynamic fluorodeoxyglucose positron emission tomography-computed tomography in rectal cancer patients. *Int J Radiat Oncol Biol Phys* 73: 456-465, 2009.

13. Antoch G, Saoudi N, Kuehl H, et al. Accuracy of whole-body dual-modality fluorine-18-2-fluoro-2-deoxy-D-glucose positron emission tomography and computed tomography (FDG-PET/CT) for tumor staging in solid tumors: Comparison with CT and PET. *J Clin Oncol* 22: 4357-4368, 2004.
14. Kantorova I, Lipska L, Belohlavek O, et al. Routine (18)F-FDG PET preoperative staging of colorectal cancer: comparison with conventional staging and its impact on treatment decision making. *J Nucl Med* 44: 1784-1788, 2003.
15. Rasanen JV, Sihvo EI, Knuuti MJ, et al. Prospective analysis of accuracy of positron emission tomography, computed tomography, and endoscopic ultrasonography in staging of adenocarcinoma of the esophagus and the esophagogastric junction. *Ann Surg Oncol* 10: 954-960, 2003.
16. Young CS, Young BL, Smith SM: Staging Hodgkin's disease with 18-FDG PET. Comparison with CT and surgery. *Clin Positron Imag* 1: 161-164, 1998.
17. Antoch G, Stattaus J, Nemat AT, et al. Non-small cell lung cancer: dual-modality PET/CT in preoperative staging. *Radiology* 229: 526-533, 2003.
18. Osman MM, Cohade C, Nakamoto Y, et al. Clinically significant inaccurate localization of lesions with PET/CT: Frequency in 300 patients. *J Nucl Med* 44: 240-243, 2003.
19. Mah K, Caldwell CB, Ung YC, et al. The impact of (18)FDGPET on target and critical organs in CT-based treatment planning of patients with poorly defined non-small-cell lung carcinoma: A prospective study. *Int J Radiat Oncol Biol Phys* 52: 339-350, 2002.
20. Ciernik IF, Dizendorf E, Baumert BG, et al. Radiation treatment planning with an integrated positron emission and computer tomography (PET/CT): A feasibility study. *Int J Radiat Oncol Biol Phys* 57: 853-863, 2003.
21. Daisne JF, Sibomana M, Bol A, et al. Tri-dimensional automatic segmentation of PET volumes based on measured source-to-background ratios: Influence of reconstruction algorithms. *Radiother Oncol* 69: 247-250, 2003.
22. Ciernik IF, Huser M, Burger C, et al. Automated functional image-guided radiation treatment planning for rectal cancer. *Int J Radiat Oncol Biol Phys* 62: 893-900, 2005.
23. Gondi V, Bradley K, Minesh M, et al. Impact of hybrid fluorodeoxyglucose positron-emission tomography/computed tomography on radiotherapy planning in esophageal and non-small-cell-lung-cancer. *Int J Radiat Oncol Biol Phys* 67:187-195, 2007.
24. Mutic S, Malyapa RS, Grigsby PW, et al. PET guided IMRT for cervical carcinoma with positive paraaortic lymph nodes: A dose escalation treatment study. *Int J Radiat Oncol Biol Phys* 55: 28-35, 2003.
25. Vrieze O, Haustermans K, De Wewer W, et al. Is there a role of FDG-PET in radiotherapy planning in esophageal carcinoma? *Radiat Oncol* 73: 269-275, 2004.
26. Topkan E, Yavuz AA, Aydin M, et al. Comparison of CT and PET-CT based planning of radiation therapy in locally advanced pancreatic carcinoma. *J Exp Clin Cancer Res* 27: 41, 2008.
27. Moureau-Zabotto L, Touboul E, Lerouge D, et al. Impact of CT and 18F-deoxyglucose positron emission tomography image fusion for conformal radiotherapy in esophageal carcinoma. *Int J Radiat Oncol Biol Phys* 63: 340-345, 2005.
28. Munley MT, Marks LB, Scarfone C, et al. Multimodality nuclear medicine imaging in three-dimensional radiation treatment planning for lung cancer. Challenges and prospects. *Lung Cancer* 23: 105-114, 1999.
29. Lammering G, De Haas D, De Ruyscher D, et al. First report on the use of dedicated combined PET-CT simulator in rectal cancer patients. *Radiother Oncol* 2004; 73(Suppl. 1): S441-S442.
30. Bassi MC, Turri L, Sacchetti G, et al. FDG-PET/CT imaging for staging and target volume delineation in preoperative conformal radiotherapy of rectal cancer. *Int J Radiat Oncol Biol Phys* 70:1423-1426, 2008.
31. Calvo FA, Domper M, Matute R, et al. 18FDG-positron emission tomography staging and restaging in rectal cancer treated with preoperative chemoradiation. *Int J Radiat Oncol Biol Phys* 58: 528-535, 2004.
32. Gearhart SL, Frassica D, Rosen R, et al. Improved staging with pre-treatment positron emission tomography/computed tomography in low rectal cancer. *Ann Surg Oncol* 13: 397-404, 2006.
33. De Geus-Oei LF, Ruers TJ, Punt CJ, et al. FDG-PET in colorectal cancer. *Cancer Imaging* 2006; 316(Suppl. 1): S71-S81.
34. Capirci C, Rampin L, Erba PA, et al. Sequential PET/CT reliably predicts response of locally advanced rectal cancer to neo-adjuvant chemo-radiation therapy. *Eur J Nucl Med Mol Imaging* 34: 1583-93, 2007.
35. Patel DA, Chang ST, Goodman KA, et al. Impact of integrated PET/CT on variability of target volume delineation in rectal cancer. *Technol Cancer Res Treat* 6: 31-36, 2007.
36. American Joint Committee on Cancer. Colon and rectum. Philadelphia, Lippincott-Raven, 2002: 113.
37. International Commission on Radiation Units and Measurements. ICRU report 62. Prescribing, recording, and reporting photon beam therapy (supplement to ICRU report 50). Bethesda, MD: ICRU; 1999.
38. Erdi YE, Mawlawi O, Larson SM, et al. Segmentation of lung lesion volume by adaptive positron emission tomography image thresholding. *Cancer* 80(Suppl. 12): 2505-2509, 1997.
39. Colorectal Cancer Collaborative Group. Adjuvant radiotherapy for rectal cancer. A systematic overview of 8,507 patients from 22 randomised trials. *Lancet* 358: 1291-1304, 2001.
40. Frass BA. The development of conformal radiation therapy. *Med Phys* 22: 1911-1921, 1995.
41. Bentzen SM. High-tech in radiation oncology: Should there be a ceiling? *Int J Radiat Oncol Biol Phys* 58: 320-330, 2004.

42. Buchmann I, Reinhardt M, Elsner K, et al. 2-(fluorine-18) Fluoro-2-deoxy-D-glucose positron emission tomography in the detection and staging of malignant lymphoma: A Bicenter trial. *Cancer* 91: 889-899, 2001.
43. Huetenschmidt B, Sautter-Bihl ML, Lang O, et al. Whole body positron emission tomography in the treatment of Hodgkin disease. *Cancer* 91: 302-310, 2001.
44. Jerusalem G, Beguin Y, Najjar F, et al. Positron emission tomography (PET) with 18F-fluorodeoxyglucose (18FDG) for the staging of low-grade non-Hodgkin's lymphoma (NHL). *Ann Oncol* 12: 825-830, 2001.
45. Talbot JN, Haioun C, Rain JD, et al. [18F]-FDG positron imaging in clinical management of lymphoma patients. *Crit Rev Oncol Hematol* 38: 193-221, 2001.
46. Pakzad F, Groves A, Ell P: The Role of Positron Emission Tomography in the Management of Pancreatic Cancer. *Semin Nucl Med* 36: 248-256, 2006.
47. Erdi YE, Rosenzweig K, Erdi AK, et al. Radiotherapy treatment planning for patients with non-small cell lung cancer using positron emission tomography (PET). *Radiother Oncol* 62: 51-60, 2002.
48. Grosu AL, Lachner R, Wiedenmann N, et al. Validation of a method for automatic image fusion (BrainLAB System) of CT data and 11C-methionine-PET data for stereotactic radiotherapy using a LINAC: First clinical experience. *Int J Radiat Oncol Biol Phys* 56: 1450-1463, 2003.
49. Erdi YE, Mawlawi O, Larson SM, et al. Segmentation of lung lesion volume by adaptive positron emission tomography image thresholding. *Cancer* 80: 2505-2509, 1997.
50. Giraud P, Grahek D, Montravers F, et al. CT and 18F-deoxyglucose (FDG) image fusion for optimization of conformal radiotherapy of lung cancers. *Int J Radiat Oncol Biol Phys* 49: 1249-1257, 2001.
51. Bradley J, Thorstad WL, Mutic S, et al. Impact of FDG-PET on radiation therapy volume delineation in non-small-cell lung cancer. *Int J Radiat Oncol Biol Phys* 59: 78-86, 2004.
52. Caldwell CB, Mah K, Ung YC, et al. Observer variation in contouring gross tumor volume in patients with poorly defined non-small-cell lung tumors on CT: The impact of 18FDGhybrid PET fusion. *Int J Radiat Oncol Biol Phys* 51: 923-931, 2001.
53. MacManus MP, Hicks RJ, Ball DL, et al. F-18 fluoro-deoxyglucose positron emission tomography staging in radical radiotherapy candidates with non-small-cell lung carcinoma. *Cancer* 92: 886-895, 2001.
54. Nestle U, Walter K, Schmidt S, et al. 18F-deoxyglucose positron emission tomography (FDG-PET) for the planning of radiotherapy in lung cancer: High impact in patients with atelectasis. *Int J Radiat Oncol Biol Phys* 44: 593-597, 1999.
55. Vanuytsel LJ, Vansteenkiste JF, Stroobant SG, et al. The impact of 18F-fluoro-2-deoxy-D-glucose positron emission tomography (FDG-PET) lymph node staging on the radiation treatment volumes in patients with non-small-cell lung cancer. *Radiother Oncol* 55: 317-324, 2000.
56. Narayan K, Hicks RJ, Jobling T, et al. A comparison of MRI and PET scanning in surgically staged locoregionally advanced cervical cancer: Potential impact of treatment. *Int J Gynecol Cancer* 11: 263-271, 2001.
57. Reinhardt MJ, Ehrhrit-Braun C, Vogelgesang D, et al. Metastatic lymph nodes in patients with cervical cancer: Detection with MR imaging and FDG-PET. *Radiology* 218: 776-782, 2001.
58. Yen TC, Ng KK, Ma SY, et al. Value of dual-phase 2-fluoro-2-deoxy-D-glucose positron emission tomography in cervical cancer. *J Clin Oncol* 21: 3651-3658, 2003.
59. Kim NK, Baik SH, Seong JS, Kim H, Roh JK, Lee KY, Sohn SK, Cho CH. Oncologic outcomes after neoadjuvant chemoradiation followed by curative resection with tumor-specific mesorectal excision for fixed locally advanced rectal cancer: Impact of postirradiated pathologic downstaging on local recurrence and survival. *Ann Surg* 244: 1024-1030, 2006.
60. Bosset JF, Magnin V, Maingon P, et al. Preoperative radiochemotherapy in rectal cancer: Long-term results of a phase II clinical trials. *Int J Radiat Oncol Biol Phys* 46: 323-327, 2000.
61. Meade PG, Blatchford GJ, Thorson AG, et al. Preoperative chemoradiation downstages locally advanced ultrasound-staged rectal cancer. *Am J Surg* 170: 609-612, 1995.
62. Berger C, de Muret A, Garaud P, et al. Preoperative radiotherapy for rectal cancer: Predictive factors of tumor downstaging and residual tumor cell density (RTCD): prognostic implications. *Int J Radiat Oncol Biol Phys* 32: 1025-1029, 1997.
63. Kim JS, Kim JS, Cho MJ, et al. Preoperative chemoradiation using oral capecitabine in locally advanced rectal cancer. *Int J Radiat Oncol Biol Phys* 54: 403-408, 2002.

### Correspondence

Dr. Melek Nur YAVUZ  
Akdeniz Üniversitesi Tıp Fakültesi  
Radyasyon Onkolojisi Anabilim Dalı  
ANTALYA / TURKEY

Tel: (+90.322) 322 82 82 /1305  
Fax: + (+90.322) 322 79 79  
e-mail: meleknur68@yahoo.com.tr